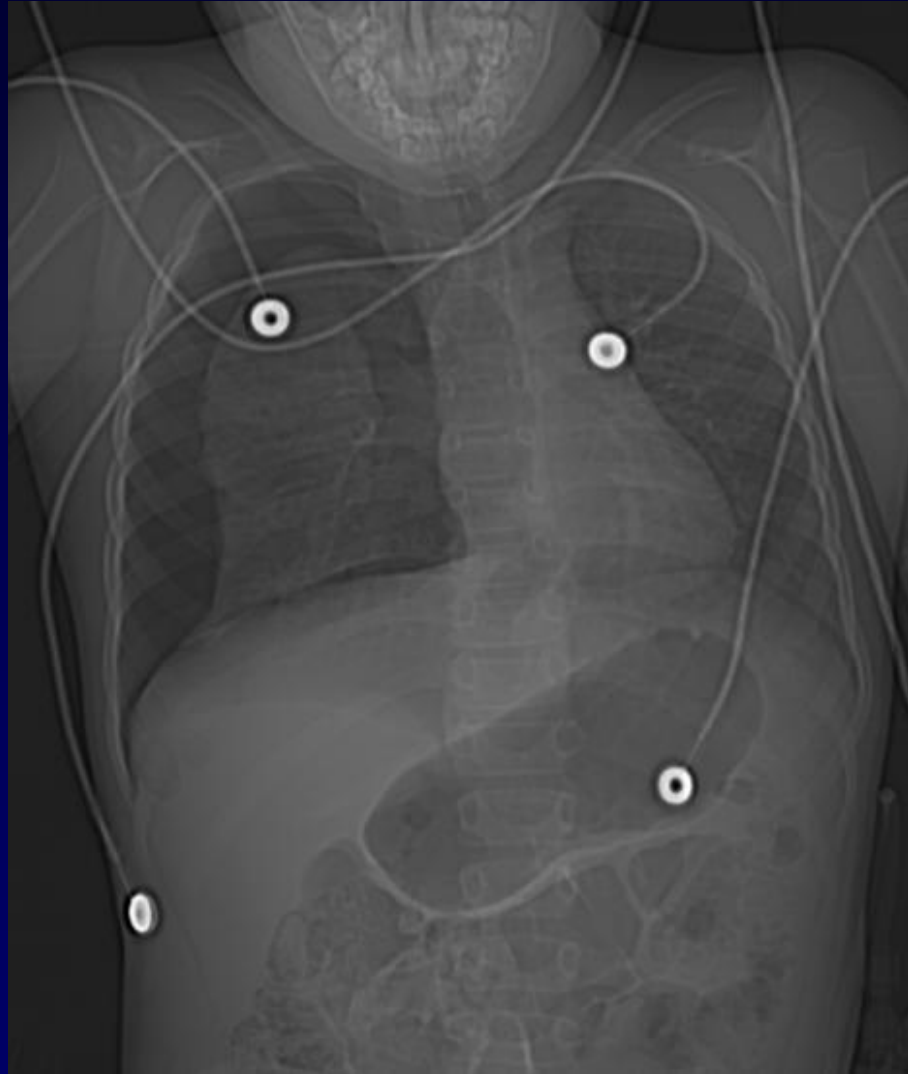

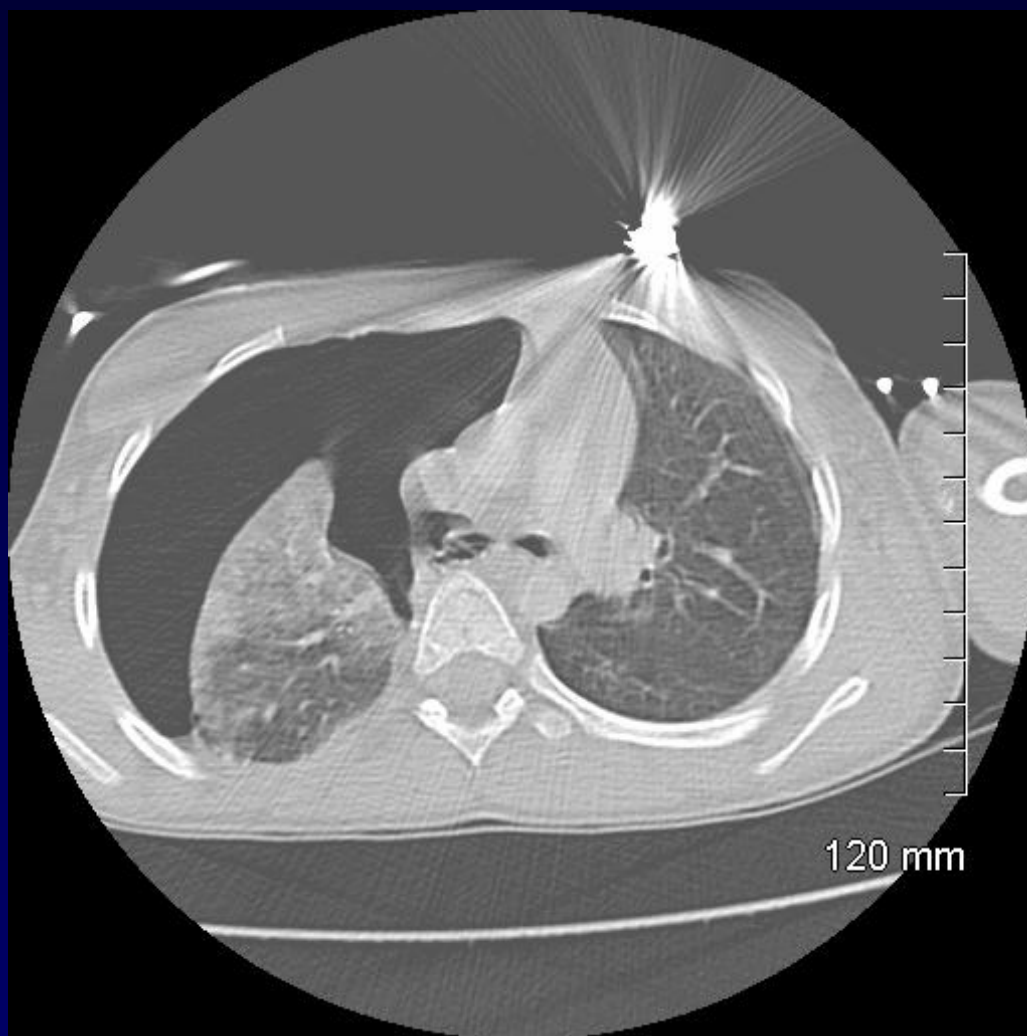


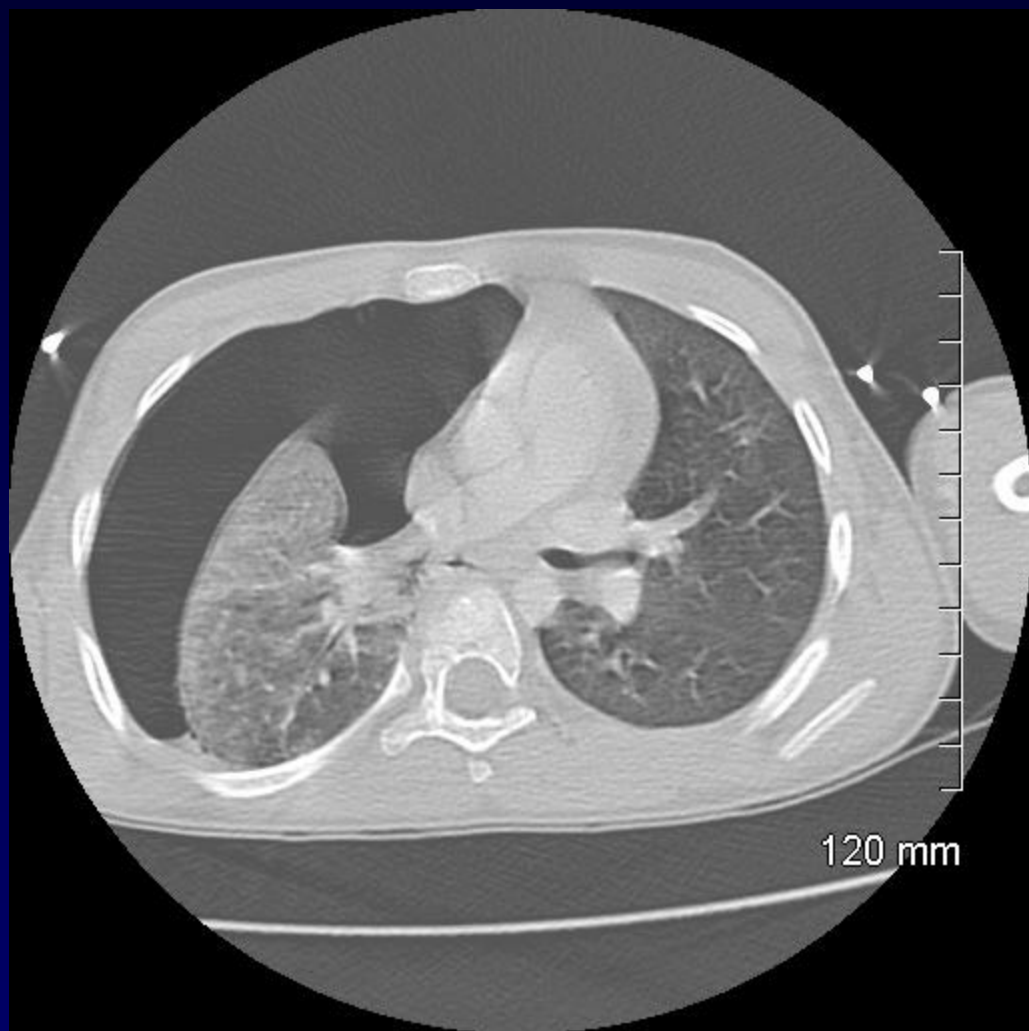
J . GIRON – P . FAJADET

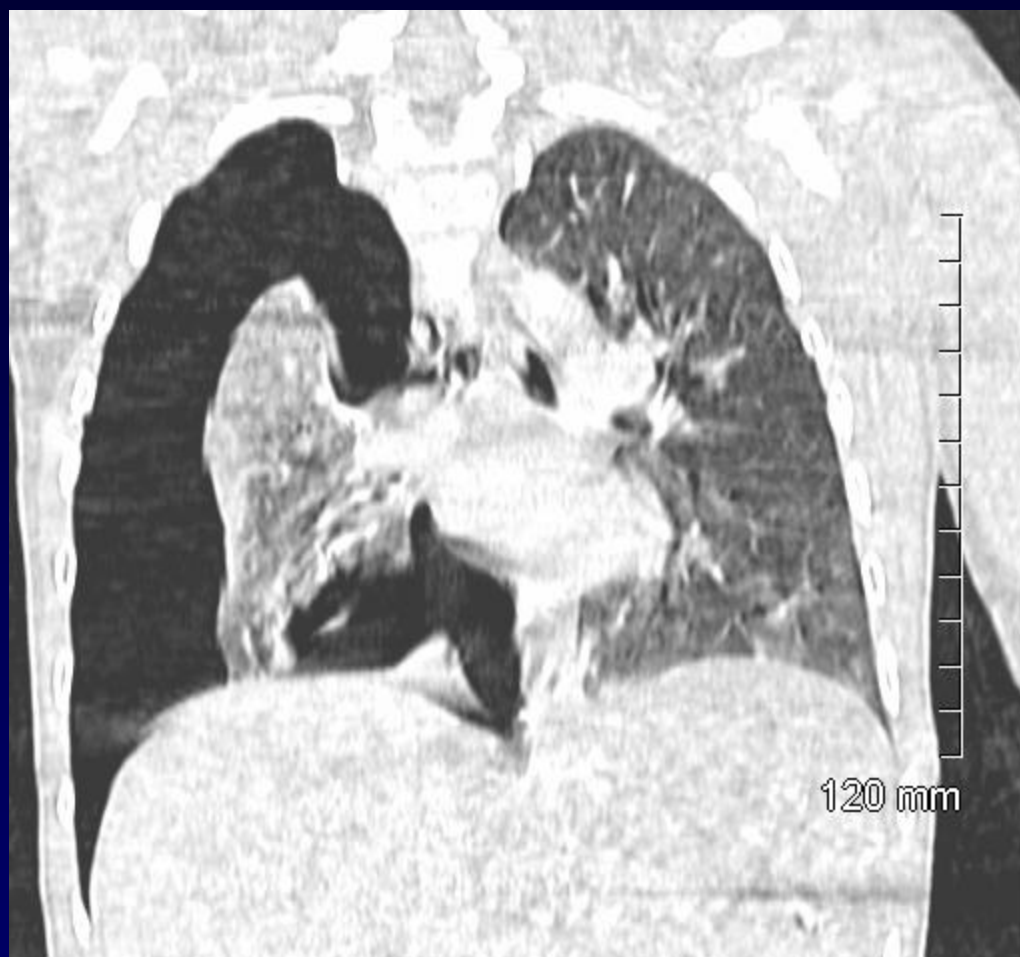H, 5 ans

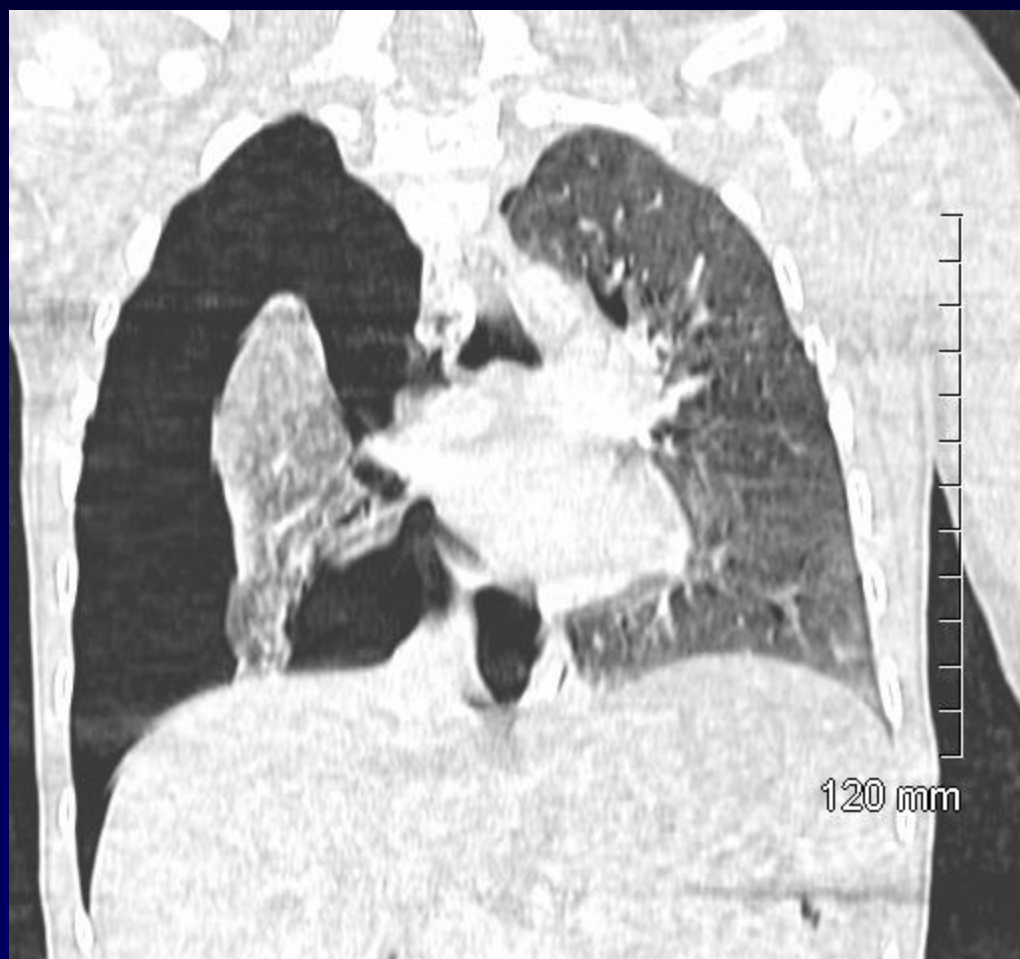TRAUMA – AVP – CEINTURE ARRIERE DROITE

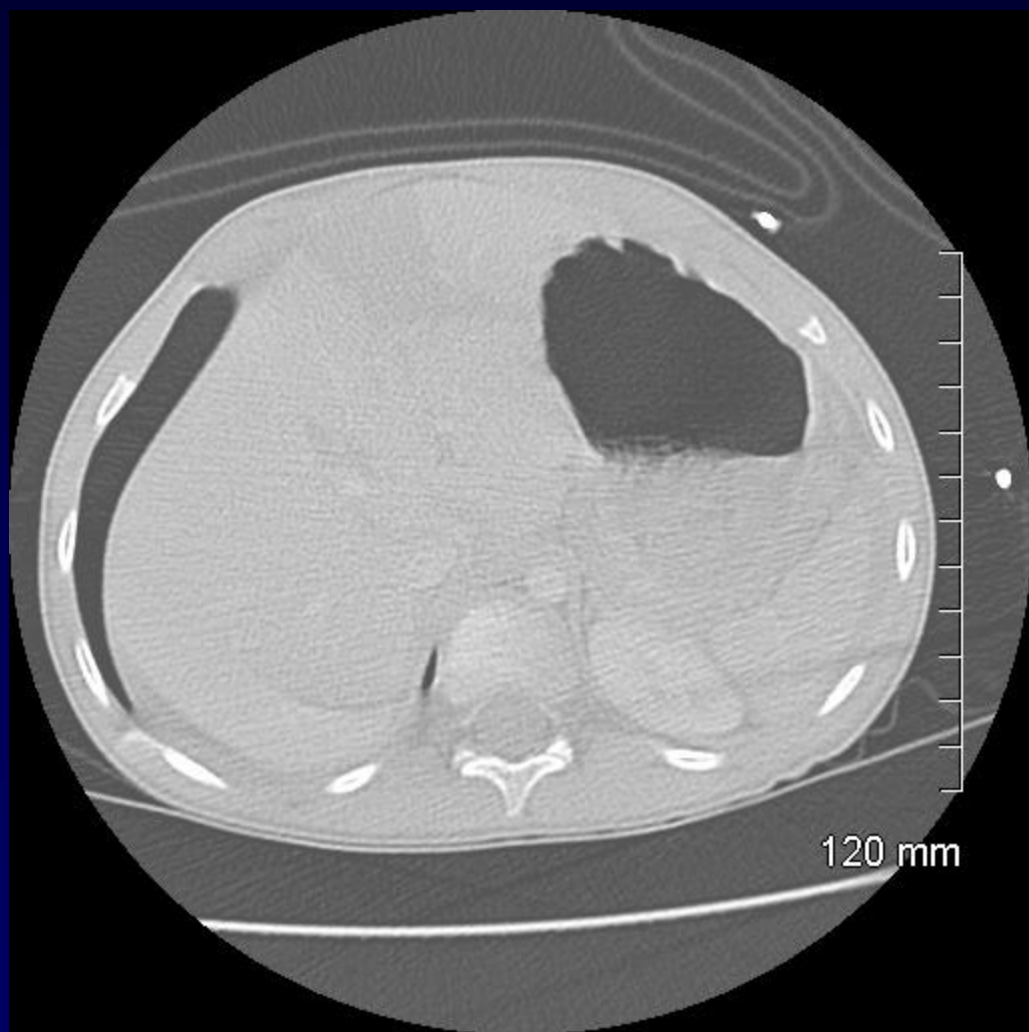






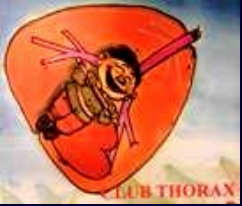







**Diagnostic ?**



# Diagnostic

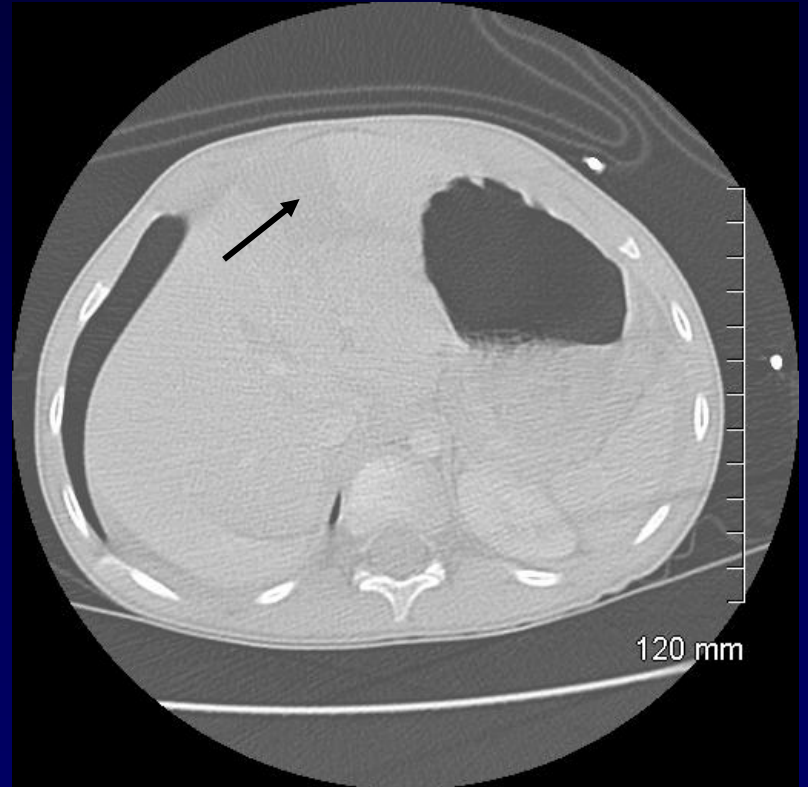
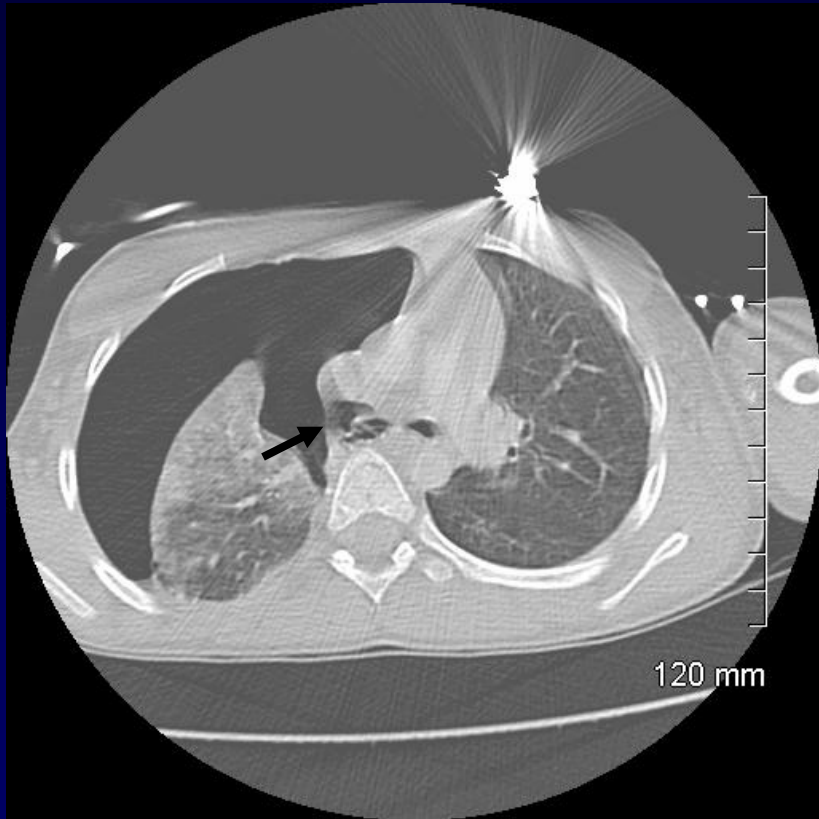
**RUPTURE BRONCHE SOUCHE DROITE**

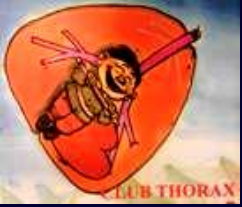**A SON ORIGINE**

**MAIS APRES LA PLEVRE MEDIASTINE**

**PNEUMO-THORAX – POUMON DROIT BASCULE**

**FRACTURE HEPATIQUE**





# Evolution-Discussion-Point fort

## CHIRURGIE REUSSIE MALGRE RETARD ( 20 H )

